

Multidisciplinary Approach to the Rehabilitation of a Crown Fracture with Glass-Fibre-Reinforced Composite: A Case Report

Ceyhan Altun, DDS, PhD; Tolga Fikret Tözüm, DDS, PhD; Günseli Güven, DDS, PhD

Contact Author

Dr. Altun
Email: ceyhanaltun@yahoo.com



ABSTRACT

Traumatic tooth injuries are common in children. When permanent teeth are involved, it can be a challenge to save these teeth. This clinical case study describes the multidisciplinary treatment of a complex crown fracture and luxation of a right maxillary incisor along with esthetic management. After periodontal surgery including guided bone regeneration and endodontic treatment, we used a glass-fibre-reinforced composite post to increase retention and distribute stress along the root. The restoration was completed using composite in an incremental technique. During follow-up appointments, clinical and radiographic examinations revealed no root canal or periodontal problems, suggesting the efficacy of the treatment in retaining the fractured tooth. Periodontal surgery with endodontic treatment is an alternative treatment for severe trauma in permanent teeth.

For citation purposes, the electronic version is the definitive version of this article: www.cda-adc.ca/jcda/vol-74/issue-4/363.html

Traumatic tooth injuries are common in children. Researchers in several countries have reported the prevalence of these injuries ranging from 6% to 37%.¹⁻³ More than 30% of accidents occur at home and about 25% in school.⁴ They may be a result of sports injuries, automobile accidents, etc., although falls are the most frequent cause.^{5,6} When the permanent teeth are involved, it can be a challenge for the child, the parents and the dentist to save these teeth. Maxillary incisors are most commonly involved in dental trauma and dental crowns are frequently damaged because of their exposed position in the dental arch.^{7,8} Traumatic injuries are next most frequent in the upper and lower lateral incisors and the upper canines.⁹

Traumatized anterior teeth require quick functional and esthetic repair, and composite materials are commonly used for esthetic restorations.¹⁰ Because of the poor mechanical resistance of these materials, attempts to strengthen them have included reinforcing their resinous matrix with fibres or glass-fibre posts.¹¹ Interlaced glass filaments improve the impact strength of composite materials.¹⁰⁻¹² They have appreciable esthetic properties, but do not easily stick to a resinous matrix.¹² In the case of a complex crown fracture, with the necessity for endodontic treatment and periodontal surgery, fibres were used to create a central support stump to restore the dental morphology.

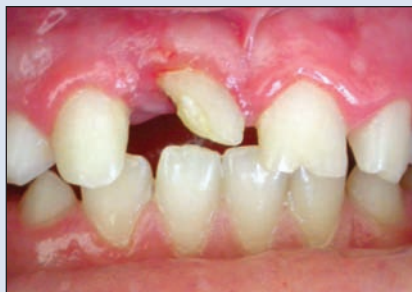

Figure 1: Clinical appearance of the right central incisor with crown fracture.

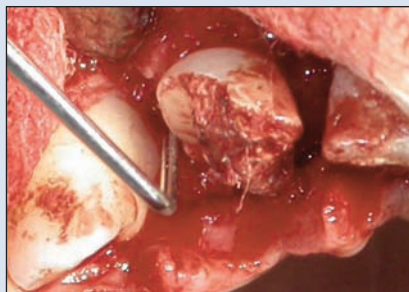


Figure 2: Intraoral view during periodontal surgery, showing a deep vertical periodontal defect.

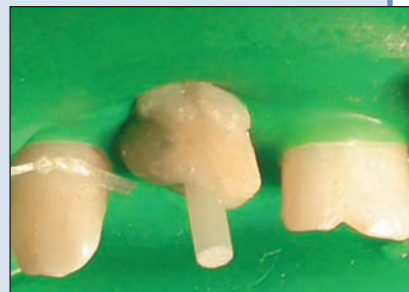

Figure 3: Intraoral view after restoration of the permanent maxillary right central incisor with a glass-fibre-reinforced composite post.

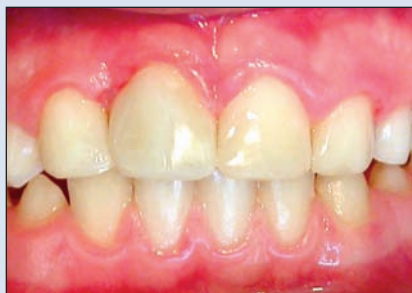

Figure 4: Final esthetic result after restoration and occlusal adjustment.

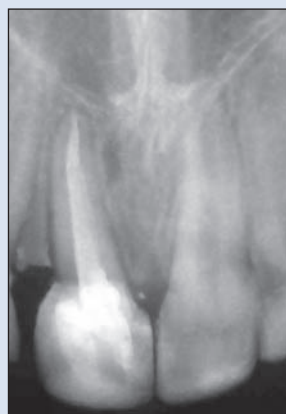

Figure 5: Follow-up periapical radiograph, one year after treatment.

Case Report

A 10-year-old girl presented to the department of pediatric dentistry with a complex crown fracture and luxation of her right maxillary incisor. She had no known allergies or systemic problems. The trauma, which was caused by a cycling accident, had occurred about one month earlier. An extraoral examination revealed swelling of the upper lip. Intraoral examination showed no lacerations or evidence of alveolar bone fracture or gingival inflammation at the gingival margin of the right maxillary incisor (**Fig. 1**). The right maxillary central incisor was luxated, showing minor mobility and slight sensitivity to heat. It responded to the electric pulp test and vitality test as nonvital. Radiology showed completed root development in the maxillary right central incisor and no other fracture or injury in the adjacent teeth. However, a deep vertical periodontal defect with an acute periodontal abscess was noted. The patient was referred to the department of periodontology where examination revealed a probing depth of 9 mm with pus formation. The treatment plan included endodontic treatment followed

by periodontal regenerative surgery involving both the departments of pediatric dentistry and periodontology.

The parents were given detailed information about the whole procedure. The child was given local anesthesia, and the root canal was instrumented and filled with calcium hydroxide paste (Calcium Hydroxide Dressing, Produits Dentaires SA, Vevey, Switzerland). Immediately afterward, a periodontal flap was reflected and the defect was debrided (**Fig. 2**). The surgical area was filled with bioglass bone substitute (PerioGlas, Nova Bone Products, Alachua, Fla.) and a resorbable collagen membrane (BioMend, Zimmer Dental, Carlsbad, Calif.) covered the surgical area. The flaps were closed using 4.0 sling sutures. The patient was prescribed oral antibiotics (amoxicillin) and 0.12% chlorhexidine gluconate for 7 days.

Ten days after surgery, the sutures were removed and uneventful healing was observed. The intracanal dressing was changed every 30 days for 4 months until tooth symptoms were negative. After cleaning and shaping, the root canal was filled with calcium hydroxide-based sealer (Sealapex, Sybron/Kerr, Indústria e Comércio Ltda,

Guarulhos, SP, Brazil) and gutta-percha using the vertical condensation technique. The gutta-percha was partly removed leaving the apical 4 mm of the filling to maintain a good seal, and the post was placed as previously described (Fig. 3).^{13,14} After etching of the coronal fragment with a 37% phosphoric acid gel for 20 seconds, the area was rinsed for 20 seconds then dried gently with air. An adhesive (Excite DSC, Ivoclar Vivadent AG, Schaan, Liechtenstein), dual-curing luting composite system (Variolink II, Ivoclar Vivadent AG) and a glass-fibre-reinforced composite root canal post (FRC Postec, Ivoclar Vivadent AG) were applied according to the manufacturer's instructions. Finally, to meet esthetic requirements for the anterior segment, the dental restoration was completed with composite (Tetric Ceram, Ivoclar Vivadent AG) using the incremental technique and occlusal adjustment was performed (Fig. 4).

After treatment, to control the periapical area, a radiograph was taken and the patient was asked to return to the clinic for follow-up every 3 months. Clinical and radiographic comparisons were repeated during these visits without any pathologic findings. A year after the treatment, clinical and radiographic examination confirmed the efficiency of the combined technique using a glass-fibre-reinforced post and composite materials. The radiographic appearance of the traumatized right central incisor was similar to that of the noninjured left central incisor (Fig. 5). The periodontal follow-up also presented no complications; all clinical periodontal indices decreased and at 12 months, periodontal probing depth was 2 mm, and gingival index, plaque index and gingival bleeding time index were all 0.

Discussion

Cast posts and cores are commonly used because of their superior mechanical properties. However, if a ceramic crown is chosen as the final restoration, the colour and opacity of the post may lead to discoloration and shadowing on the gingival and cervical areas of the tooth. To solve this esthetic problem, tooth-coloured fibre and zirconium post systems were introduced; these are capable of resisting occlusal loads and have light transmission characteristics similar to those of natural teeth.^{15,16} In addition, these materials allow us to restore the tooth with minimal sacrifice of additional tooth structure. Improvements in esthetic materials allow excellent results in restoration of damaged teeth. However, because of the poor mechanical strength of composites, various approaches have been attempted to strengthen them, including reinforcing their resinous matrix with fibres or glass-fibre posts.¹⁰

The potential of fibre-reinforced materials in restorative dentistry has been appreciated for some time.¹⁷ Interlaced glass filaments improve the impact strength of composite materials and have appreciable esthetic

properties, but do not easily stick to the resinous matrix.¹² Various changes have been made to glass-fibre post composition, radiopacity and shape.¹⁸⁻²⁰ The manufacturers have recently developed posts that are radiopaque, thus easily seen on radiographs. Modifications in post configuration have been made to achieve better adaptation to root canal shape. For example, for translucent glass-fibre posts, light transmission through the post permits the use of a light-cured adhesive or dual-cure resin cement.²⁰ The translucent glass-fibre post has a modulus of elasticity similar to that of dentin and offers adequate mechanical properties.^{19,21} Transmission of light through the post also makes it possible to light-cure the resin cement and the bonding system in only one clinical step, thus simplifying and shortening the clinical procedure.²²

In the current case, we used an adhesive, dual-cure luting composite system and a glass-fibre-reinforced composite root canal post. This technique can reinforce the restored parts and, probably, increase durability and survival. The results of *in vitro*^{23,24} and *in vivo*¹⁵ studies indicate that nonmetal posts can be used when coronal dentin remains and the crown is well supported by the remaining tooth structure. With a modulus of elasticity similar to dentin, the fibre post can reduce the concentration of stress and, thus, the rate of catastrophic root fracture compared with cast posts.²⁵⁻²⁷

During follow-up examinations, the efficiency of the combined technique of glass-fibre-reinforced composite root canal post and composite resins was confirmed. In fact, no restoration fractures or dimensional changes were found during follow-up examinations. In this case, a bonding system and a light-cured resin were used to bond the post and restore the crown. The bonding of a post to the tooth structure should improve the prognosis of the restored tooth by increasing post retention¹⁰ and by reinforcing the tooth structure.

Compared with alternative techniques, such as a composite resin restoration, screw-post, cast-metal posts and dentin pins, reattachment using a fibre post offers several advantages. It provides immediate esthetic and functional rehabilitation of the fractured tooth. Minimal patient cooperation is required, and the treatment takes little time and is, thus, readily accepted by the patient. Patient cooperation is one of the most important criteria in tooth conservation. In our case, our patient's cooperation was excellent and the endodontic treatment with periodontal therapy was successful.

As well as endodontic treatment, periodontal therapy, including regenerative methods, has a pivotal place in multidisciplinary treatments. In the present case, periodontal regenerative procedures were used as described previously.²⁸ Hong and others²⁹ describe a case in which the distal part of a geminated maxillary lateral incisor was resected, root canal treatment was performed and the distal vertical defect was filled with a bone regenerative

material to achieve bone and periodontal attachment. The authors report reduced periodontal probing depth. Naaman and others²⁸ recommend the application of bone regenerative materials to vertical bone defects to achieve periodontal bone regeneration around maxillary central incisors traumatized by an inadequate orthodontic appliance. A multidisciplinary approach including bone grafting restored the lost parts of the periodontal structures. In our case, bone gain in the vertical periodontal defect and reduction in probing depth were achieved. Periodontal parameters, including gingival, plaque and gingival bleeding time indexes, also decreased during follow-up visits without any pathologic mobility. Bone regeneration was radiologically evident after 12 months of follow-up.

Conclusion

We describe multidisciplinary management of a dental trauma, leading to conservation of the tooth and its permanent restoration. We suggest that using glass-fibre-reinforced composite root canal posts and composite materials can be a simple and efficient procedure for the treatment of anterior traumatized teeth with excellent esthetic and functional results. Further, traumatized teeth with periodontal vertical defects can be successfully treated by guided bone regeneration during long-term follow-up. ✦

THE AUTHORS



Dr. Altun is an assistant professor in the department of pediatric dentistry, Center of Dental Sciences, Gülhane Medical Academy, Ankara, Turkey.



Dr. Tözüm is an associate professor in the department of periodontology, faculty of dentistry, Hacettepe University, Ankara, Turkey.



Dr. Güven is an assistant professor in the department of pediatric dentistry, Center of Dental Sciences, Gülhane Medical Academy, Ankara, Turkey.

Correspondence to: Dr. Ceyhan Altun, GATA Dis Hekimligi Bilimleri Merkezi, Pedodonti Ana Bilim Dalı, Etlik/Ankara, Turkey.

The authors have no declared financial interests in any company manufacturing the types of products mentioned in this article.

This article has been peer reviewed.

References

- Laloo R. Risk factors for major injuries to the face and teeth. *Dent Traumatol* 2003; 19(1):12–4.
- Traebert J, Peres MA, Blank V, Böell Rda S, Pietruza JA. Prevalence of traumatic dental injury and associated factors among 12-year-old school children in Florianópolis, Brazil. *Dent Traumatol* 2003; 19(1):15–8.

- Rajab LD. Traumatic dental injuries in children presenting for treatment at the Department of Pediatric Dentistry, Faculty of Dentistry, University of Jordan, 1997–2000. *Dent Traumatol* 2003; 19(1):6–11.
- Blinkhorn FA. The aetiology of dento-alveolar injuries and factors influencing attendance for emergency care of adolescents in the north west of England. *Endod Dent Traumatol* 2000; 16(4):162–5.
- Andreasen JO. Etiology and pathogenesis of traumatic dental injuries. A clinical study of 1,298 cases. *Scand J Dent Res* 1970; 78(4):329–42.
- O’Neil DW, Clark MV, Lowe JW, Harrington MS. Oral trauma in children: a hospital survey. *Oral Surg Oral Med Oral Pathol* 1989; 68(6):691–6.
- Petti S, Tarsitani G. Traumatic injuries to anterior teeth in Italian schoolchildren: prevalence and risk factors. *Endod Dent Traumatol* 1996; 12(6):294–7.
- Leroy RL, Aps JK, Raes FM, Martens LC, De Boever JA. A multidisciplinary treatment approach to a complicated maxillary dental trauma: a case report. *Endod Dent Traumatol* 2000; 16(3):138–42.
- Glendor U. On dental trauma in children and adolescents. Incidence, risk, treatment, time and costs. *Swed Dent J Suppl* 2000; 140:1–52.
- Vitale MC, Caprioglio C, Martignone A, Marchesi U, Botticelli AR. Combined technique with polyethylene fibers and composite resins in restoration of traumatized anterior teeth. *Dent Traumatol* 2004; 20(3):172–7.
- Samadzadeh A, Kugel G, Hurley E, Aboushala A. Fracture strengths of provisional restorations reinforced with plasma-treated woven polyethylene fiber. *J Prosthet Dent* 1997; 78(5):447–50.
- Vallittu PK, Vojtkova H, Lassila VP. Impact strength of denture polymethyl methacrylate reinforced with continuous glass fibers or metal wire. *Acta Odontol Scand* 1995; 53(6):392–6.
- Mattison GD, Delivanis PD, Thacker RW Jr, Hassell KJ. Effect of post preparation on the apical seal. *J Prosthet Dent* 1984; 51(6):785–9.
- Goodacre CJ, Spolnik KJ. The prosthodontic management of endodontically treated teeth: a review of literature. Part II. Maintaining the apical seal. *J Prosthodont* 1995; 4(1):51–3.
- Freedman GA. Esthetic post-and-core treatment. *Dent Clin North Am* 2001; 45(1):103–16.
- Koutayas SO, Kern M. All-ceramic posts and cores: the state of the art. *Quintessence Int* 1999; 30(6):383–92.
- Bradley JS, Hastings GW, Johnson-Nurse C. Carbon fiber reinforced epoxy as a high strength, low modulus material for internal fixation plates. *Biomaterials* 1980; 1(1):38–40.
- Love RM, Purton DG. The effect of serrations on carbon fibre posts-retention within the root canal, core retention, and post rigidity. *Int J Prosthodont* 1996; 9(5):484–8.
- Asmussen E, Peutzfeldt A, Heitmann T. Stiffness, elastic limit, and strength of newer types of endodontics posts. *J Dent* 1999; 27(4):275–8.
- Vichi A, Grandini S, Davidson CL, Ferrari M. An SEM evaluation of several adhesive systems used for bonding fiber posts under clinical conditions. *Dental Mater* 2002; 18(7):495–502.
- Dietschi D, Romelli M, Goretti A. Adaptation of adhesive posts and cores to dentin after fatigue testing. *Int J Prosthodont* 1997; 10(6):498–507.
- Lui JL. Composite resin reinforcement of flared canals using light-transmitting plastic posts. *Quintessence Int* 1994; 25(5):313–9.
- Sidoli GE, King PA, Setchell DJ. An in vitro evaluation of a carbon fiber-based post and core system. *J Prosthet Dent* 1997; 78(1):5–9.
- Stockton LW, Williams PT. Retention and shear bond strength of two post systems. *Oper Dent* 1999; 24(4):210–6.
- Bergman B, Lundquist P, Sjögren U, Sundquist G. Restorative and endodontic results after treatment with cast post and cores. *J Prosthet Dent* 1989; 61(1):10–5.
- Cormier CJ, Burns DR, Moon P. In vitro comparison of the fracture resistance and failure mode of fiber, ceramic and conventional post systems at various stages of restoration. *J Prosthodont* 2001; 10(1):26–36.
- Malferrari S, Monaco C, Scotti R. Clinical evaluation of teeth restored with quartz fiber-reinforced epoxy resin posts. *Int J Prosthodont* 2003; 16(1):39–44.
- Naaman NB, Chaptini E, Taha H, Mokbel N. Combined bone grafting and orthodontic treatment of an iatrogenic periodontal defect: a case report with clinical reentry. *J Periodontol* 2004; 75(2):316–21.
- Hong HH, Tsai AI, Liang CH, Kuo SB, Chen CC, Tsai TP, and other. Preserving pulpal health of a geminated maxillary lateral incisor through multidisciplinary care. *Int Endod J* 2006; 39(9):730–7.